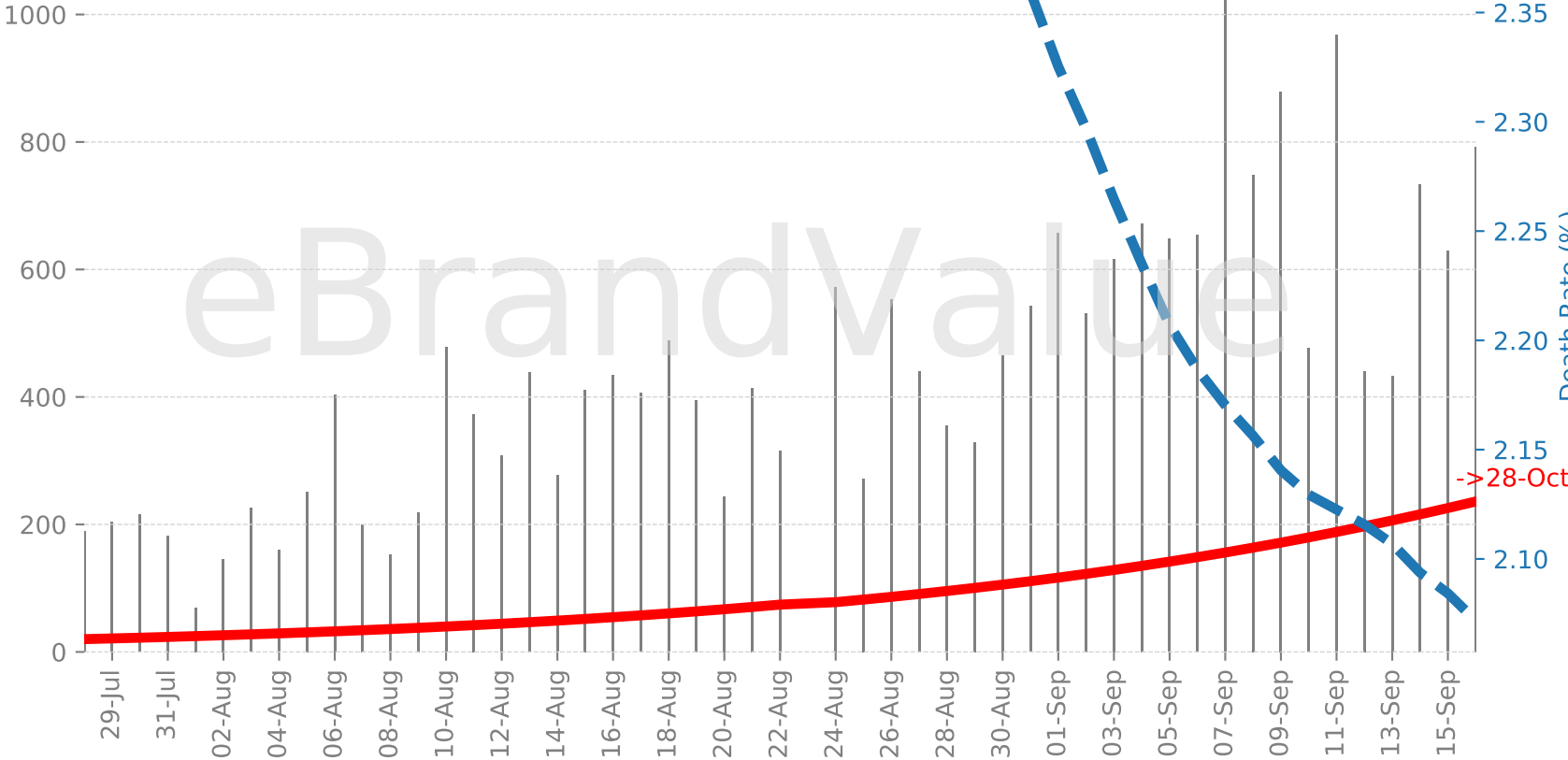


Reported Cases



28-Oct